

# Prescribing **Hydrogen Peroxide** In The Treatment Of **Periodontal Disease**

Tanya Dunlap, PhD

**A**ntibiotics used for the treatment of periodontal disease have come under increasing scrutiny in recent years. One concern lies in the rise of bacteria resistant to antibiotics, complicating treatment and posing general health risks.

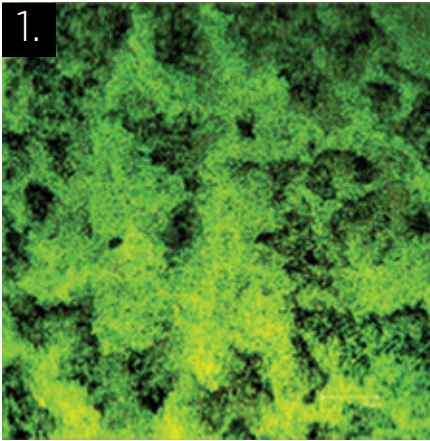
Some patients want to avoid antibiotics and their side effects altogether. Many dentists have raised concerns about antibiotic long-term efficacy. An alternative antimicrobial to be used between office visits is a 1.7% hydrogen peroxide gel delivered into periodontal pockets with a sealed prescription tray. Hydrogen peroxide has a long and safe track record in dentistry and has been used in tray delivery for more than 10 years to treat periodontal disease. Classified in the United States as an oral debriding agent and an oral wound cleanser, peroxide is an effective antimicrobial for chronic oral wounds inducing periodontal disease.

According to the Centers for Disease Control and Prevention, antibiotic-resistant infections outside of hospital settings were rare until recently. The rise in bacterial resistance to antibiotics now poses serious health threats. In the United States, at least two million people are infected with antibiotic resistant bacteria each year and 23,000 of these patients die from the infections. The CDC estimates that nearly half of antibiotics currently prescribed are not needed and urges antibiotic stewardship: using antibiotics only when they are needed to treat disease, choosing the right antibiotics, and administering them in the right way in every case.<sup>1</sup>


Many patients are wary of the side effects of systemic antibiotics including diarrhea, abdominal cramping, nausea, vomiting, and fever. These conditions usually resolve when the antibiotic therapy ends, but in more serious cases the drugs wipe out healthy bacteria in the gut, and can create conditions for *Clostridium difficile* to proliferate. This resulting intestinal infection, which has also been documented after antibiotic therapy for routine dental work,<sup>2</sup> is so difficult to treat that fecal transplants may be needed to re-establish a healthy bacterial balance. As recently as 2013, the treatment consisted of delivering feces from a healthy person into the gut of the sick patient via a tube or enema. These early successes led to the development of pill formulations of fecal matter by 2015, thereby reducing the costs, risks, and patient aversions to the earlier delivery methods.<sup>3</sup>

In periodontal therapy, localized antibiotic usage may avoid the side effects of systemic antibiotics, but the placement of the localized drugs has to be repeated often and the costs mount. In two studies evaluating the benefits of minocycline spheres placed into periodontal pockets measuring  $\geq 5$ mm, an average of 31 sites were treated at baseline, at three months, and at six months.<sup>4</sup>

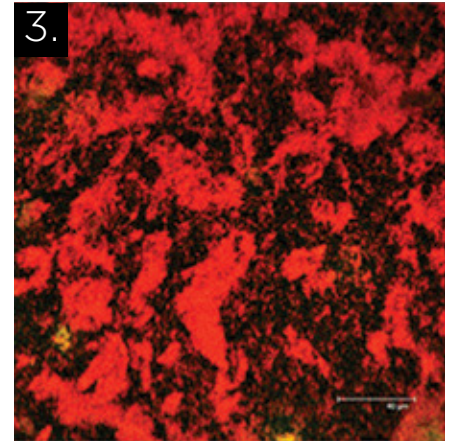
This kind of repetitive, short-term therapy is typical in the treatment of periodontal disease. Periodontitis is a classic biofilm-based disease and, “like other biofilm infections, is refractory to antibiotic agents and host defenses because the causative microbes live in complex communities that persist



1. Confocal microscope image showing Live/Dead kit results on 3-day-old *Streptococcus mutans* UA159 control group. Cell walls are intact (green).



2. Confocal microscope image showing Live/Dead kit results on 3-day-old *Streptococcus mutans* UA159 test group with 1.7% hydrogen peroxide gel (Perio Gel®, QNT Anderson, Bismarck, ND) topically applied for 5 minutes. Cell walls are compromised (yellow/orange) but not lysed.



3. Confocal microscope image showing Live/Dead kit results on 3-day-old *Streptococcus mutans* UA159 test group with 1.7% hydrogen peroxide gel (Perio Gel®, QNT Anderson, Bismarck, ND) topically applied for 15 minutes. Cell walls are lysed and cells are dead (red).

despite challenges that range from targeted antibiotic agents to phagocytosis.”<sup>5</sup> Whether the disease is prompted by pathogenic bacteria or by the host inflammatory response that creates conditions ripe for bacterial infections,<sup>6</sup> once the biofilm has developed with favorable ecological conditions, it stubbornly persists.

### Scientific Trials For The Use Of Hydrogen Peroxide To Treat Periodontal Disease

An effective and less costly alternative to antibiotics in the treatment of periodontal disease is a low concentration of hydrogen peroxide. Two clinical trials evaluating a 1.7% hydrogen peroxide gel (Perio Gel®, QNT Anderson, Bismarck, ND) administered into periodontal pockets via a sealed prescription tray (Perio Tray®, Perio Protect, St. Louis, MO) as an adjunctive therapy to debridement and scaling, documented more significant reductions in bleeding on probing and pocket probing depths compared to mechanical therapy alone.<sup>7</sup>

The sealed tray delivery is important because peroxide needs to be administered deep and held in place long enough to work effectively as an oral debriding agent and cleanser for the infected wounds in periodontal pockets. There is a long history of safe, prolonged use of low levels (3% or less) of hydrogen peroxide to reduce plaque and gingivitis indices, but the therapeutic delivery of peroxide to prevent or treat periodontitis requires mechanical access to subgingival pockets.<sup>8</sup>

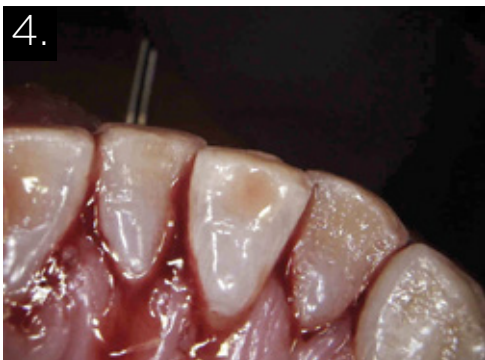The sealed periodontal tray has been shown to place the peroxide gel into pockets as deep as 9mm.<sup>9</sup>

To be effective, the tray not only needs to deliver the medication subgingivally but also to hold it in place. *In vitro* studies testing five and 10-minute exposures of a gel with 1.7% hydrogen peroxide on *Streptococcus mutans* biofilms demonstrated that 10 minutes was needed for an effective kill rate.<sup>10</sup> Additional studies at Allegheny Singer Research Institute examined five and 15-minute exposures of the 1.7% peroxide gel. Here again the benefits of a longer exposure time were observed (Figs. 1-3).

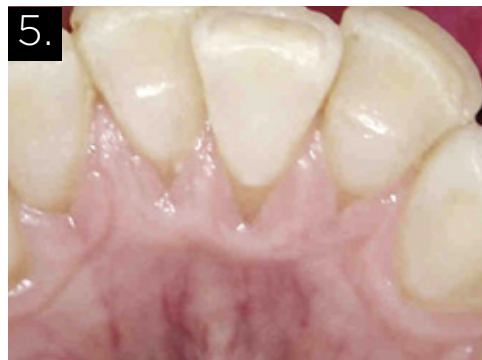### CLINICAL USE OF HYDROGEN PEROXIDE IN TRAYS TO TREAT PERIODONTAL DISEASE

In clinical use, the tray administration of the peroxide gel solves significant treatment challenges. This includes the limitations of traditional homecare with toothbrush, rinse and floss that do not reach deep enough into periodontal pockets. Tray delivery is not technique sensitive. Patients simply wear the tray with the gel for 10-15 minutes at a time. The non-invasive tray technology appeals to patients as do the side effects of the low concentration of peroxide: whiter teeth and fresher breath.

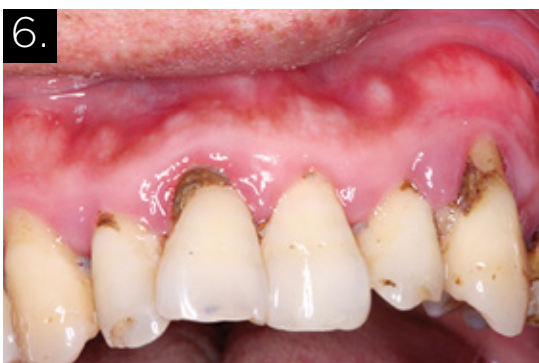For 66 patients with refractory periodontal disease, the addition of the tray-administered peroxide gel one to two times a day for 10 minutes reduced whole mouth bleeding on probing by 75% ( $p < 0.001$ ) for an evaluation period of up to five years. Pocket depths that were examined ranged from 3-9mm.



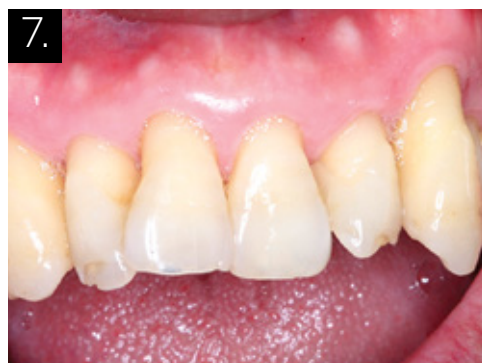4. Patient exhibited bleeding at 101 sites on June 8, 2016. 37% of pockets measured 4-6mm. Scaling and localized antibiotic therapy were completed in early 2014. The patient completed three-month maintenance therapy for the following two years. Prescription tray delivery of 1.7% hydrogen peroxide gel began on June 23, 2016, 3 times a day for 15 minutes. Image courtesy of Dr. Brian Daub, Scottsdale, AZ.



5. July 7, 2016, two weeks after tray delivery started, the patient returned to the office and 7 sites were recorded with bleeding on probing. 1-2 mm pocket probing depth reductions were recorded. Image courtesy of Dr. Brian Daub, Scottsdale, AZ.



6. Patient presented in January 2015 with 100% bleeding on probing and 77% of pocket depths  $\geq$ 4mm, the deepest measuring 7mm. A year after initial therapy, bleeding on probing was recorded at 25% of all sites. Prescription tray therapy began April 2016, 2 times a day for 15 minutes. Image courtesy of Dr. Bruce Cochrane, Fort Dodge, IA.



7. One month after prescription tray delivery began, the patient exhibited no bleeding on probing. The deepest pocket measured 5mm and 74% of pockets were  $\leq$ 3mm. This image, taken July 2016, three month after tray delivery started, illustrates the comprehensive results. Image courtesy of Dr. Bruce Cochrane, Fort Dodge, IA.

The reductions were documented early in the study and were sustained throughout the evaluation period. There were no statistically significant differences reported between smokers and non-smokers. The tray delivery benefited both groups.<sup>11</sup>

Two case examples provide a better understanding of how the prescription tray delivery works in clinical settings. Both patients in these cases completed initial periodontal therapy and had at least one year of maintenance therapy. Both continued to exhibit pockets  $>$ 3mm and bleeding on probing during maintenance and before tray delivery of peroxide gel was prescribed. Two to four weeks after starting tray therapy with

peroxide gel, bleeding on probing was significantly reduced. Pocket depth reductions were also noted (Figs. 4-5 & 6-7).

In addition to its oral debridement and wound cleansing action, the oxygenating action of hydrogen peroxide is believed to have therapeutic benefits. Oxygen released by the peroxide when the gel is delivered into periodontal pockets has been hypothesized to change the microenvironment of the pocket and account for recorded changes in the microflora.<sup>12</sup>

If the disease causes an ecological shift – a change in the microenvironment in favor of the pathogenic bacteria – then modifying the ecology of the periodontal pocket should help

the host heal. Biofilm formation is not a haphazard process. Early colonizers are primarily aerobic bacteria. The next bacteria to join the community, the middle colonizers, are largely facultative anaerobes that are capable of aerobic and anaerobic respiration. Not only do these bacteria consume the waste products from the early colonizers, they also consume oxygen, modifying the microenvironment of the periodontal pockets and creating conditions for the later colonizers, particularly the gram negative obligate anaerobes, to join the community. As inflammation develops and crevicular fluid flow increases, the proteins in the fluid provide an ample food source for biofilm growth.

The goal of the tray-delivered oxygenating agent is to create ecological conditions in which the survival of periodontal pathogens is unsustainable and microbial homeostasis can be re-established. The regular administration of the oxygenating agent, similar to (but more pleasant than) a fecal treatment described above, modifies the microenvironment to help re-establish a healthy bacterial balance. More research needs to be done to examine how and why the oxygenating therapy works, but it appears that the oxidizing and oxygenation action of the peroxide is key to localized bacterial management (microbial homeostasis) and host healing. **OH**

---

Tanya Dunlap, PhD is the Managing Director for Perio Protect, LLC where she has worked since 2005. She coordinates clinical research involving prescription tray delivery. She also offers CE courses on the science behind prescription tray delivery and the important implications of the research data.

Oral Health welcomes this original article.

## REFERENCES

1. <http://www.cdc.gov/drugresistance/about.html>
2. Denise Grady, "When Pills Fail, This, er, Option Provides a Cure." New York Times, January 16, 2013.

3. <http://www.openbiome.org/press-releases/2015/10/28/fecal-transplant-pills-large-scale-production-begins-following-successful-dosing-study>
4. [http://www.accessdata.fda.gov/drugsatfda\\_docs/label/2008/050781s012lbl.pdf](http://www.accessdata.fda.gov/drugsatfda_docs/label/2008/050781s012lbl.pdf)
5. Schaudinn, C. Gorur A, Keller D, Sedghizadeh PP, Costerton JW. Periodontitis: An Archetypical Biofilm Disease. J Am Dent Assoc. 2009 Aug;140(8):978-86.
6. Bartold, PM and Van Dyke TE. Periodontitis: a host-mediated disruption of microbial homeostasis. Unlearning learned concepts. Periodontol 2000. 2013;62(1):203-17.
7. Putt M, Mallatt M, Messmann L, and Proskin H. A 6-month clinical investigation of custom tray application of peroxide gel with or without doxycycline as adjuncts to scaling and root planning for treatment of periodontitis. Am J Dent. 2014;27:273-284. Putt M and Proskin H. Custom Tray Application of Peroxide Gel as an Adjunct to Scaling and Root Planing in the Treatment of Periodontitis: Results of a Randomized, Controlled Trial after 6 Months. J Clin Dent. 2013;24:100-107. Putt M and Proskin H. Custom Tray Application of Peroxide Gel as an Adjunct to Scaling and Root Planing in the Treatment of Periodontitis: A Randomized, Controlled Three-Month Clinical Trial. J Clin Dent. 2012;23(2):48-56.
8. Marshall MV, Cancro LP, Fischman SL. Hydrogen Peroxide: A Review of Its Use in Dentistry. J Periodontol 1995;66:786-96.
9. Putt et al. 2014, 2013, 2012. Dunlap T, Keller D, Marshall M, Costerton J, Schaudinn C, Sindelar B, and Cotton J. Subgingival Delivery of Oral Debriding Agents: A Proof of Concept. J Clin Dent. 2011 Nov;XXII(5):149-158.
10. Dunlap et al.
11. Cochrane RB and Sindelar B. Case Series Report of 66 Refractory Maintenance Patients Evaluating the Effectiveness of Topical Oxidizing Agents. J Clin Dent. 2015;26:109-114.
12. <https://providers.perioprotect.com/wp-content/uploads/2015/11/1186SEM-Poster.pdf>. Dunlap et al.

**NEWCOM**  
BUSINESS MEDIA INC.

**oralhealth**

Reprinted with permission from Oral Health Group Magazine -  
A Newcom Business Media Inc Publication