

The Journal of Clinical Dentistry®

THE INTERNATIONAL JOURNAL OF APPLIED DENTAL RESEARCH

www.JClinDent.com

Volume XXII

2011

Number 5

SENIOR EDITOR

Robert C. Emling, EdD

EDITORIAL BOARD

Caren M. Barnes, RDH, MS

Annerose Borutta, Prof.Dr.med.habil.

Robert L. Boyd, DDS, MEd

Kenneth H. Burrell, DDS, MS

Mark E. Cohen, PhD

David Drake, MS, PhD

Heinz Duschner, Prof.Dr.

William Michael Edgar, PhD, DDS, FDSRCS

Denise Estafan, DDS, MS

Stuart L. Fischman, DMD

Rosa Helena Miranda Grande, DDS, PhD

John J. Hefferren, PhD

Elliot V. Hersh, DMD, PhD

Mark E. Jensen, DDS, PhD

Carl J. Kleber, MSD, PhD

Israel Kleinberg, DDS, PhD, DSc

Karl F. Leinfelder, DDS, MS

Jonathan Mann, DMD, MSc

Kenneth Markowitz, DDS

Milton V. Marshall, PhD, DABT

Pier Francesco Porciani, MD, MScD

Howard M. Proskin, PhD

Mark S. Putt, MSD, PhD

Bruce R. Schemehorn, MS

Warren Scherer, DDS

Jon B. Suzuki, DDS, PhD, MBA

Jason M. Tanzer, DMD, PhD

Norman Tinanoff, DDS, MS

Henry O. Trowbridge, DDS, PhD

Richard I. Vogel, DMD

James S. Wefel, PhD

Anthony E. Winston, BSc

Wayne T. Wozniak, PhD

Stefan Zimmer, Prof. Dr. med dent.

PUBLISHER

Stephen M. Siegel

Subgingival Delivery of Oral Debriding Agents: A Proof of Concept

Tanya Dunlap, PhD Duane C. Keller, DMD

**Perio Protect LLC
St. Louis, MO, USA**

Milton V. Marshall, PhD

**University of Texas Health Science Center at Houston
Houston, TX, USA**

J. William Costerton, PhD

**Allegheny General Hospital and Allegheny-Singer Research Institute
Pittsburgh, PA, USA**

Christoph Schaudinn, PhD

**Robert Koch Institute
Berlin, Germany**

Betty Sindelar, PT, PhD John R. Cotton, PhD

**Ohio University
Athens, OH, USA**

Subgingival Delivery of Oral Debriding Agents: A Proof of Concept

Tanya Dunlap, PhD Duane C. Keller, DMD

Perio Protect LLC
St. Louis, MO, USA

Milton V. Marshall, PhD

University of Texas Health Science Center at Houston
Houston, TX, USA

J. William Costerton, PhD

Allegheny General Hospital and Allegheny-Singer Research Institute
Pittsburgh, PA, USA

Christoph Schaudinn, PhD

Robert Koch Institute
Berlin, Germany

Betty Sindelar, PT, PhD John R. Cotton, PhD

Ohio University
Athens, OH, USA

Abstract

- **Objective:** This study is a proof of concept to determine the efficacy of a custom-fabricated tray in placing antimicrobial and debriding agents in the periodontal pockets of persons with active gingival infections. Localized subgingival delivery of antimicrobial and antibiotic agents is routinely employed as adjunctive therapy for the treatment and management of periopathogens associated with periodontal disease. Because these delivery techniques often face time constraints and impose temporary restrictions on patient brushing and flossing, a custom-formed prescription dental tray can be used to deliver and maintain medications in periodontal pockets between office visits and without brushing or flossing restrictions. The ability of this tray to maintain sufficient concentrations of medication in the periodontal pockets to have a therapeutic effect is evaluated here with theoretical modeling and practical application.
- **Methods:** Hydrogen peroxide is an oral debriding agent and oral wound cleanser with antimicrobial properties. The debriding effect of 1.7% hydrogen peroxide gel was tested *in vitro* on *Streptococcus mutans* biofilm using glass carriers for collection. Diffusion modeling tested the potential of the customized tray to place hydrogen peroxide gel into the sulcus in the presence of crevicular fluid flow. Changes in periodontal microflora with scanning electron microscopy analysis of *in vivo* paper point site sampling were analyzed before and after a thin ribbon of 1.7% hydrogen peroxide gel (approximately 0.7 gm) and a subtherapeutic dose (three drops) of Vibramycin® (50 mg/5 ml) were placed via Perio Trays® into periodontal pockets, ranging from 4–8 mm at daily prescribed intervals for two to five weeks.
- **Results:** *In vitro* results indicate that 1.7% hydrogen peroxide gel breaks down the exopolysaccharide slime and cell walls of *S. mutans*, and begins to debride the cells from glass carriers within 10 minutes. Diffusion modeling indicates that hydrogen peroxide can penetrate into the deeper pockets (9 mm), but also its concentration in these deep pockets will increase over wearing time in the absence of degradation by peroxidases and catalase. Site sampling data confirm diffusion modeling results, with evidence that medication delivered with the prescription tray reduced subgingival bacterial loads and enhanced healing of corresponding oral tissues.
- **Conclusion:** The prescription Perio Tray effectively placed medication in the gingival sulcus. Mathematical modeling indicated Perio Tray placement of hydrogen peroxide gel in periodontal pockets with depths up to 9 mm over 15 minutes treatment time was theoretically possible. Pathology reports reveal reductions in subgingival bacterial loads and improvements in pretreatment pocket depths of up to 8 mm after 1.7% hydrogen peroxide and Vibramycin Syrup were prescribed for use with the Perio Tray. The *in vitro* analysis indicating that hydrogen peroxide is the active and effective oral debriding agent needs to be confirmed with additional studies.

(J Clin Dent 2011;22:149–158)

Introduction

Periodontal disease is the host response to oral biofilm microbial “triggers”¹⁻³ that can result in localized tissue inflammation, gingival ulcerations with bleeding, tissue destruction, and bone loss leading to deep periodontal pocket formation that can culminate

in tooth loss.^{4,5} A local periodontal inflammatory response may also adversely affect the host systemic immune response and general health.⁶⁻⁸ For clinical practitioners, these localized and systemically adverse effects are underscored by the prevalence of periodontal disease and the insufficiencies inherent in current

treatment methods, of which scaling and root planning (SRP) is the accepted gold standard in non-surgical treatment. The benefits of SRP^{9,10} are well recognized, but significant limitations occur with SRP, including mechanical inability to remove all bacterial cells, resulting in biofilm regeneration that requires repetitive mechanical procedures and the risks of bacteremia associated with mechanical debridement and scaling. Faced with these limiting situations, practitioners employ adjunctive therapies¹¹ or surgery.

Periodontitis is a persistent inflammatory response to bacterial growth in slime-enclosed communities that, like all classic biofilms, resists clearance by host defenses and systemic antibiotic therapy.^{1,4,12,13} The ability of biofilms to persist in spite of activated host responses lies at the root of their persistence. Physical biofilm debridement has developed as the gold standard in the treatment of biofilm infections as it is in dentistry with SRP, but it is impossible to eliminate all bacteria in the biofilm with SRP and recolonization can occur.¹⁴⁻¹⁶

Mechanical debridement can have the specific limitation of stimulating biofilm regeneration. In one study, mechanical removal of 50% of the initial biofilm resulted in a four-fold increase in biofilm growth. Subsequent 75% removal of the regrowth resulted in a three-fold increase over that present from the first regrowth under magnification analysis.¹⁷ A biofilm that is mechanically disturbed can thus increase its reproductive capabilities in response to the physical forces used to perturb it.

Given the limitations with mechanical procedures, adjunctive antibiotic therapies are employed to improve treatment outcomes.^{18,19} Antibiotics effectively kill individual planktonic cells and some of the peripheral, actively dividing bacteria in the biofilm, but have little effect on the dormant core enclosed in the protective slime matrix.^{20,21} In order for the antibiotics to work more effectively, the matrix has to be removed and the dormant core stimulated; however, when the matrix is mechanically debrided, the remaining biofilm cells are stimulated, prompting rapid regeneration until the biofilm returns to a protected stable population stasis for which additional SRP is often necessary in a cyclical fashion.²² Therefore, most patients with chronic or aggressive periodontitis have SRP performed every three to six months.

Risks of bacteremia associated with mechanical debridement and scaling^{23,24} increase with repetitive use of SRP. For most healthy adults, the host immune system is capable of managing the inflammatory response induced by bacteremia during periodontal procedures, but for the millions of immunocompromised individuals and adults with diabetes, cardiovascular disease, joint replacements, and other inflammatory illnesses, an increase in the chronic systemic inflammatory burden may pose additional health risks.²⁵ Given these potential risks, it would be beneficial to have a treatment modality that could reduce localized periodontal inflammation before mechanical debridement, and thus decrease the possibility of bacteremia.

For some cases, surgery is necessary. When pathogenic bacteria are capable of penetrating phagocytic and non-phagocytic cells, they evolve to survive within the host cells,²⁶⁻²⁸ which can result in the development of host granulomatous tissue.^{29,30} In these cases, the only appropriate therapy is surgical removal of the internally infected tissues.

When surgery is not required or after it has been performed, adjunctive chemical therapies can enhance treatment outcomes.^{10,11} Recently, new attention has been paid to peroxide usage as a viable subgingival^{1,31-34} and supragingival³⁵ antibiofilm agent. Aqueous $\leq 3\%$ hydrogen peroxide is a known oral debriding agent and wound cleanser.³⁶ It has been formulated in mouthrinses, dentifrices, and gels for topical application, most commonly for tooth whitening.^{37,38} Researchers are also interested in the disinfectant properties of hydrogen peroxide. The hydroxyl radical formed from hydrogen peroxide decomposition, especially in the presence of iron (Fe^{3+}), has been shown to kill 99.99% of oral periopathogens and 99.999% *Streptococcus mutans* (*S. mutans*) bacteria within three minutes.³⁹

One problem with chemotherapeutic treatment is the delivery and maintenance of peroxides in the sulcus. The sulcus is a unique space for chemotherapeutic treatment modalities because it is accessible topically, but the salient problem of overcoming gingival crevicular fluid flow tends to limit chemical contact in the gingival space. The most effective topical administration of peroxides for biofilm management appears to be tray delivery of a gel formulation.^{33,35,40} If peroxides can debride subgingival planktonic cells of the biofilm and significantly reduce the peripheral elements of biofilms, the peroxides may shift biofilm communities into a defensive growth mode, limiting their ability to reproduce or trigger inflammation.

This study, to evaluate the potential of a custom-fabricated dental tray to retain medication in the sulcus a sufficient amount of time for the medication to have a therapeutic effect, has three distinct parts. The first shows *in vitro* debridement results of 1.7% hydrogen peroxide gel. The second is a theoretical exercise evaluating the potential for prescription Perio Tray® (Perio Protect, LLC, St. Louis, MO, USA) delivery of 1.7% hydrogen peroxide gel into the sulcus against the force of crevicular fluid flow. The third evaluates the practical application and efficacy of using customized trays for localized subgingival delivery of medication based on pathology reports documenting *in vivo* subgingival biofilm changes after medication is placed into periodontal pockets via prescription Perio Trays.

Material and Methods

In Vitro Debridement with 1.7% Hydrogen Peroxide Gel

In vitro assessments were conducted to confirm the debriding action of 1.7% hydrogen peroxide gel (Dakota Pharmacy, Bismarck, ND, USA) on oral biofilm using the LIVE/DEAD® system developed by Molecular Probes (Invitrogen, Carlsbad, CA, USA).⁴¹ The assessment of viability involves staining preparations with propidium iodide, which penetrates the compromised bacterial wall of dead bacteria and binds to their DNA so the cells appear in a rich red color. Bacteria with intact cell walls exclude propidium iodide, and are stained green by the Syto 9 counter stain. Bacteria that are injured with partially compromised cell walls stain an orange color. The viability of bacteria is determined by assessing the proportion of stained red, orange/yellow, and green bacteria, recorded at the moment at which the population was stained.

S. mutans (strain UA 159) were inoculated in Brain Heart Infusion (OXOID LTD., Basingstoke, UK) with 2% sucrose (Bethesda

Research Laboratories, Gaithersburg, MD, USA), into MatTek glass bottom microwell plates (MatTek Corporation Ashland, MA, USA), which were incubated for 24 hours at 37°C, 5% CO₂ of an orbital shaker. After 24 hours under a laminar hood, media from each plate were removed and new media were replaced. Plates were incubated for another 24 hours under similar conditions to form a mature biofilm on the third day.

The plates were aseptically removed from the incubator, and exposed to the 1.7% hydrogen peroxide gel and to gel with all excipients except hydrogen peroxide for five or 10 minutes prior to rinsing with sterile phosphate buffered saline (BioWhittaker/Lonza Walkersville, MD, USA) and exposure to the LIVE/DEAD® BacLite™ (Invitrogen, Carlsbad, CA, USA) staining procedure. A control series was similarly prepared, and all manipulations were conducted to prevent the removal of biofilm by mechanical forces for comparison. Following the staining procedure, the stained plates were examined using a Leica TCS-SP2 confocal scanning laser microscope (CSLM).

Diffusion Modeling

The modeling tests the theory that the prescription tray system results in a concentration of hydrogen peroxide (*c*) delivered and maintained in the gingival sulcus or periodontal pocket during the period of treatment. A simple mass transport model was used to estimate the ability of hydrogen peroxide to penetrate the periodontal pocket over time as a function of distance.

In Vivo Subgingival Effects of Medication Delivered with the Perio Tray

A retrospective review of pathology reports from a private general dental clinic identified records from four patient (three men, one woman, age range 33–71 years) who had selected treatment with the custom-fabricated Perio Tray for delivery of medication before SRP, either because of previous mechanical periodontal treatment failure or because they refused SRP treatment. Because of their treatment status, the patients were asked to consent to biofilm samplings as a diagnostic adjunct to their plan of care. Sterile Absorbent Points (#504 Henry Schein Inc., Melville, NY, USA) were held in place for 10 seconds in 19 total periodontal pockets before chemotherapeutic treatment began with the Perio Tray, and again two to five weeks after daily treatment began. None of the patients had had SRP three months prior to or during the course of this treatment.

Paper points were prepared for scanning electron microscopy (SEM) by dehydration in a graded ethanol series, critical point dried, mounted on a stub, sputter coated with a 20 nm layer of platinum, and examined with an XL 30 S, FEG SEM (FEI Company, Hillsboro, OR, USA) operating at 5 kV in the secondary electron mode.

All paper points were systematically scanned and documented with overview, regional, and detail images. The approximate dimension of each biofilm colony could be calculated based on the overview and regional images. Furthermore, the approximate number of bacteria/colony/layers was counted, and six basic morphotypes were defined (spiral-rods, short-rods [1:2 width: length], middle-long rods [$> 1:2 - < 1:7$], long rods [$> 1:7$], flagellated rods, filamentous-rods, and coccus-like bacteria).

These morphotypes were counted in each biofilm colony at three standard areas of 100 μm^2 and averaged. The results were multiplied by the colony area and height. The sum for every morphotype over all colonies yielded the total amount of bacteria per paper point.

After initial SEM analysis of paper points, the periodontal pockets were treated with 1.7% hydrogen peroxide gel and a sub-clinical dose (three drops per tray) of Vibramycin® Syrup (50 mg/5 ml, Pfizer, New York, NY, USA), topically placed via prescription Perio Trays. Paper point biofilm sampling was repeated two to five weeks after daily Perio Tray delivery of medication.

The accuracy of the SEM image analysis approach can be only described as a rough approximation whose exactness is not more than one order of magnitude. Therefore, only significant changes are detected.

Results

In Vitro Debridement with 1.7% Hydrogen Peroxide Gel

When *S. mutans* biofilms generated *in vitro* were examined by the LIVE/DEAD technique, without gel treatment, the majority of the millions of bacterial cells in these coherent and luxuriant biofilms were alive (green) with uncompromised bacterial walls (Figure 1). In the micrograph, intact bacterial cells, approximately 0.61 μm in diameter, are seen to be embedded in an exopolysaccharide (EPS) matrix.

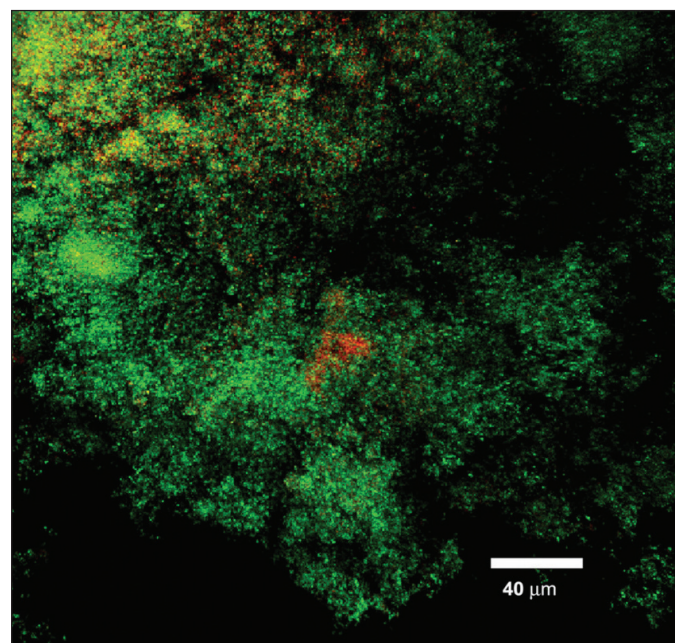


Figure 1. Confocal micrograph of untreated control *S. mutans* biofilm, showing large numbers of live (green) cells, with a few membrane-compromised (orange) cells.

S. mutans are a good choice for testing because, in contrast to many subgingival bacteria, this biofilm produces large amounts of EPS matrix that act as an additional protection barrier for the bacteria, increasing the challenge for matrix decomposition and debridement.⁴² In further contrast to subgingival bacteria, *S. mutans* is a mostly aerobic growing organism, able to handle larger amounts of the peroxide, which makes it less susceptible to the debriding action of the 1.7% hydrogen peroxide gel.

When *S. mutans* biofilms were treated for five minutes with 1.7% hydrogen peroxide gel and examined using the LIVE/DEAD technique, bacterial wall integrity of only a small proportion of the biofilm cells were compromised, and only a small proportion of them stained orange to yellow (Figure 2). However, when these biofilms were exposed to the 1.7% peroxide gel for 10 minutes, virtually all of the bacterial walls were disrupted (red; Figure 3). Most of the cells disintegrated and released their DNA as a tangled “skein.” It can be concluded that, at some point between five and 10 minutes, the chosen concentration of peroxide eradicates virtually all of the cells in the *S. mutans* biofilm.

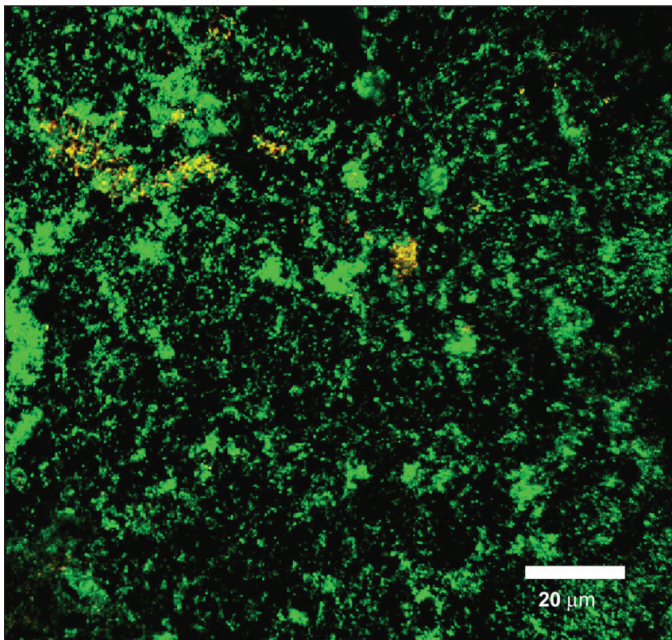


Figure 2. Confocal micrograph of *S. mutans* biofilm exposed to the 1.7% hydrogen peroxide gel for 5 minutes. Most of the coccoid cells are intact (green). The number of membrane-compromised cells (yellow) is similar to that seen in untreated biofilms.

As a control for this experiment, a gel with all excipients except the active ingredient, hydrogen peroxide, was used on *S. mutans* biofilm. Exposure to this gel for 10 minutes left the biofilm almost completely unaffected (Figure 4) in that very large areas showed only living (green) cells. In some small areas some bacterial walls were compromised (orange), but these were in the same proportion seen in untreated biofilms.

These results demonstrate that a 10-minute exposure to a 1.7% hydrogen peroxide aqueous gel can debride bacterial cell walls within a typical dental biofilm. The modeling below evaluates the potential of hydrogen peroxide gel delivery in the sulcus against gingival crevicular fluid, which occurs in the periodontal pocket.

Diffusion Modeling

In modeling the geometry of the area of diffusion, only the molars of a typical adult mouth were considered. The length of the cross-sectional area of this space was considered as the average length of a molar from mesial to distal. After measuring six molars three times each, the average length was determined as 8.88 mm. Given that a dental probe is able to fit into the periodontal pocket when disease is present, the width of a typical dental probe (0.83

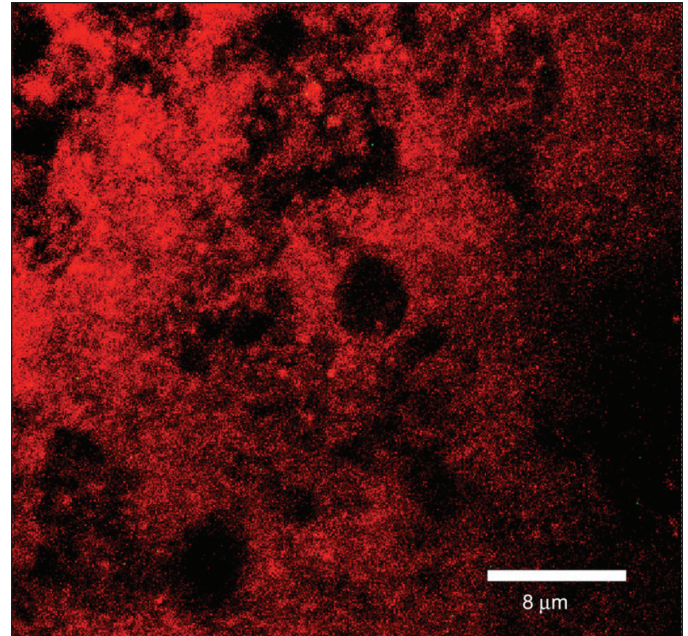


Figure 3. Confocal micrograph of a *S. mutans* biofilm treated for 10 minutes with the 1.7% hydrogen peroxide gel. All of the bacteria are degraded (red) and only a few faint cell profiles remain because the cell walls have been compromised and disintegrated, releasing their DNA as a tangled fibrous mass.




Figure 4. Confocal micrograph of *S. mutans* biofilm treated for 10 minutes with a gel containing 0% hydrogen peroxide. Note the clear predominance of living (green) cells in this control preparation.

mm) was used as the width of the cross-sectional area at the gingival-tooth interface. The depth of this space was considered as a range from 4–9 mm, reflecting the variation in pocket-probing depth associated with periodontal disease severity. Because both lingual and buccal surfaces are considered with pocket-probing depth analyses, two rectangular spaces were included in this modeling to represent both of these surfaces.

Prior studies have demonstrated that GCF flow rate increases with periodontal disease, exhibiting a range of 1.8 to 137.0 $\mu\text{L}/\text{h}$

with a mean of $45.7 \pm 35.7 \mu\text{l/h}$.⁴³ The flow rates were indicative of pocket depths greater than 4 mm, bleeding on probing at greater than 40% of the sites, and clinical attachment levels greater than 4.5 mm. These characteristics are consistent with the “typical patient” receiving treatment with the prescription trays.⁴⁴ For subsequent calculations, the flow rate was converted to a fluid velocity (v) by dividing the flow rate (Q) by the cross-sectional area (A) or

$$v = Q / A$$

This resulted in a velocity of $0.861 \times 10^{-3} \text{ mm/s}$.

Reducing the problem to one dimension, the distance along the tooth root is considered the positive x direction, with the origin at 0 mm pocket probing depth. The governing equation for this diffusion problem is then

$$\frac{\partial c}{\partial t} = -v \frac{\partial c}{\partial x} + D \frac{\partial^2 c}{\partial x^2}$$

where c is the concentration of hydrogen peroxide as a function of distance x (pocket depth) and time t .⁴⁵ The velocity (v) flows out of the tooth, and the constant D is the coefficient of diffusion. From prior studies, the coefficient of diffusion for a 10% solution of hydrogen peroxide was given as $1.48 \text{ cm}^2/\text{day}$.⁴⁶ Although the treating concentration of hydrogen peroxide is lower (1.7%), the 10% diffusion coefficient is a reasonable approximation for the treatment concentration in this exercise. The first term on the right side of the equation reflects the process of convection where fluid flow lowers the concentration of hydrogen peroxide, while the second term describes hydrogen peroxide diffusion against the concentration gradient. If the fluid velocity drops to 0, the above equation reduces to Fick’s law of diffusion.

In order to solve the equation, initial and boundary conditions had to be assumed: no concentration of hydrogen peroxide is present in the pocket at time = 0; the concentration of hydrogen peroxide in the tray at $x = 0$ is c_0 ; and no hydrogen peroxide leaves the base of the periodontal pocket, assumed to be $x = 9$ for this problem (this is considered a no flux condition at $x = 9$). In addition, the concentration of hydrogen peroxide in the tray c_0 was modeled as a decreasing amount to account for the change in degradation and outflow. Because of the changing hydrogen peroxide concentration in the tray, no steady state will be achieved.

The time-dependent solution was coded into Matlab (Version 7.4; Natick, MA, USA) using finite difference analogues, and

simulated for 15 minutes of treatment. The plot in Figure 5 shows the simulation.

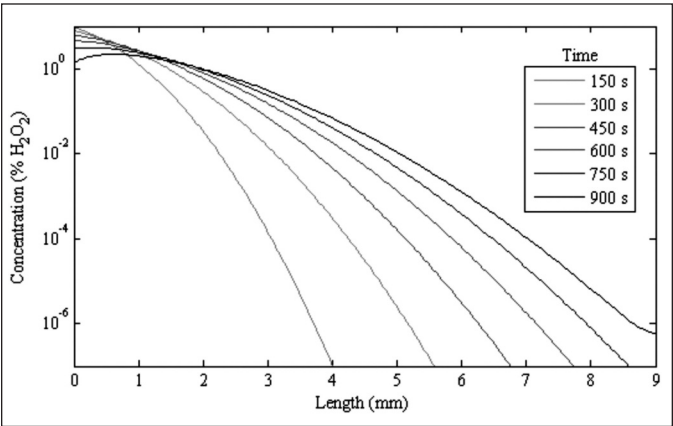


Figure 5. The simulated results show the concentration of hydrogen peroxide into the pocket increases with the length of time the peroxide remains applied.

This analysis indicates hydrogen peroxide held in the Perio Trays can diffuse into the periodontal pockets over time. Even with a relatively large GCF flow, the diffusion enters 9 mm deep pockets within the 15-minute time period studied here. Thus, throughout the time that a patient would wear the prescription Perio Tray, the concentration of hydrogen peroxide in the deeper pockets improves, indicating that even with GCF there is an increasing concentration in the deeper areas.

In Vivo Subgingival Effects of Medication Delivered with the Perio Tray

Tables I–IV detail microbial descriptions provided by SEM analysis in pathology reports for 19 total periodontal pockets from four patients. Examples of SEMs from the pathology reports are presented in Figures 6–9, and they are representative of the results seen from each sampling site before and after treatment with 1.7% hydrogen peroxide gel and three drops of Vibramycin Syrup delivered via the Perio Tray.

Patient 1 had Type II periodontal disease on arrival at the clinic. Pathology reports record sites analyzed evidenced bleeding on probing before treatment, and absence of bleeding on probing after four times daily use of the Perio Tray subgingival placement of medication for five weeks. Pocket probing depth decreased 1–2 mm during this time, and one of three sites had no bacteria recovered after five weeks of treatment. Patient 2 had

Table I					
Retrospective Compilation of Microbiological Data from Pathology Reports for Male Patient with Type 2 Periodontal Disease					
Patient 1—Male, Periodontal Disease Type II—Treatment Duration 5 Weeks, 4 × Day, 15 Minutes					
	Site	PPD	BOP	Microbial Reduction	Microbial Description Based on Scanning Electron Micrograph
Before	24 mb	4 mm	yes		Extensive presence of biofilm (~5 × 10 ⁷ bacteria) with notable high percentage of Treponema-like morphotypes.
After		3 mm	no	99.1%	Multilayered biofilm (~5 × 10 ⁵ bacteria) composed primarily of short rods, long rods and coccus-like morphotypes.
Before	6 db	4 mm	yes		Relatively little amount of biofilm (~5 × 10 ⁴ bacteria) dominated by Coccus-like morphotypes.
After		3 mm	no	100.0%	No bacteria could be found on the entire paper point, only large numbers of eukaryotic cells.
Before	27 mb	4 mm	yes		Abundant biofilm (~5 × 10 ⁷ bacteria) in which coccus-like bacteria and rods of different length were found.
After		2 mm	no	99.4%	Polymicrobial biofilm (~5 × 10 ⁵ bacteria) with predominance of filamentous-like morphotypes, as formed by many Actinomyces species.

Table II**Retrospective Compilation of Microbiological Data from Pathology Reports for Female Patient with Type 1 Periodontal Disease**

Patient 2— Female, Periodontal Disease Type I—Treatment Duration 5 Weeks, 2 × Day, 10 Minutes					
	Site	PPD	BOP	Microbial Reduction	Microbial Description Based on Scanning Electron Micrograph
Before	14 mb	4 mm	yes		Dense, multi-layered biofilm ($\sim 1 \times 10^6$ bacteria) in which only Treponema-like bacteria and rods of different length were found.
After		2 mm	no	100.0%	Only eukaryotic cells found; no evidence of bacteria.
Before	3 mb	4 mm	yes		Great number of Treponema-like bacteria in a very densely composed biofilm ($\sim 1 \times 10^5$ bacteria).
After		2 mm	no	100.0%	Many eukaryotic cells of different types; no evidence of bacteria.
Before	12 db	4 mm	yes		Patchy groups of bacteria ($\sim 1 \times 10^4$ bacteria) together with eukaryotic cells.
After		1 mm	no	100.0%	Many large eukaryotic cells; no evidence of bacteria.
Before	30 db	4 mm	yes		Poly-microbial biofilm ($\sim 5 \times 10^6$ bacteria) consisting to a large extent of Treponema-like morphotypes.
After		1 mm	no	99.3%	Few spots with filamentous and coccus-like bacteria biofilm ($\sim 5 \times 10^4$ bacteria) together with many eukaryotic cells.

Table III**Retrospective Compilation of Microbiological Data from Pathology Reports for Male Patient with Type 4 Periodontal Disease**

Patient 3—Male, Periodontal Disease Type IV—Treatment Duration 2 Weeks, 6 × Day, 15 Minutes					
	Site	PPD	BOP	Microbial Reduction	Microbial Description Based on Scanning Electron Micrograph
Before	31 mb	8 mm	yes		Multi-layered biofilm (5×10^6 bacteria) with a high number of Treponema-like morphotypes.
After		6 mm	no	99.96%	Only very sparse biofilm patches (1×10^3 bacteria) and many eukaryotic cells.
Before	2 ml	5 mm	yes		Biofilm (1×10^7 bacteria) with bacteria partly embedded in extracellular matrix.
After		3 mm	no	95.0%	Multi-layered biofilm ($\sim 1 \times 10^6$ bacteria) predominantly composed of mid-long rods.
Before	30 dl	8 mm	yes		Poly-microbial biofilm (1×10^7 bacteria) with characteristic long rods.
After		3 mm	no	95.0%	Biofilm ($\sim 1 \times 10^5$ bacteria) with different rod morphologies, coccus-like bacteria and filamentous bacteria.
Before	31 ml	9 mm	yes		Biofilm (5×10^5 bacteria) in which Treponema-like morphotypes contributed $\sim 50\%$ of all bacteria.
After		4 mm	no	99.3%	Dense layer of eukaryotic cells; no evidence of bacteria.
Before	25 dl	4 mm	yes		Large, multi-layered biofilm (5×10^8 bacteria) with fusiform bacteria and Treponema-like morphotypes.
After		2 mm	no	100.0%	Large number of eukaryotic cells; no evidence of bacteria.
Before	27 dl	4 mm	yes		Biofilm (5×10^7 bacteria) in which fusiform bacteria and short rods were frequently found as well as coccus-like morphotypes.
After		3 mm	no	100.0%	Eukaryotic cells; no evidence of bacteria.

Table IV**Retrospective Compilation of Microbiological Data from Pathology Reports for Male Patient with Type 4 Periodontal Disease**

Patient 4—Male, Periodontal Disease Type IV—Treatment Duration 2 Weeks, 6 × Day, 15 Minutes					
	Site	PPD	BOP	Microbial Reduction	Microbial Description Based on Scanning Electron Micrograph
Before	14 dl	7 mm	yes		Biofilm ($\sim 1 \times 10^7$ bacteria) with large numbers of long and short rods, as well as Treponema-like bacteria.
After		5 mm	yes	100.00%	Many eukaryotic cells; no evidence of bacteria.
Before	12 db	8 mm	yes		Multi-layered biofilm ($\sim 5 \times 10^6$ bacteria) in which Treponema-like morphotypes predominated.
After		4 mm	no	99.4%	Biofilm ($\sim 5 \times 10^4$ bacteria) composed of a majority of Treponema-like bacteria.
Before	20 dl	5 mm	yes		Patches of biofilm ($\sim 1 \times 10^6$ bacteria) with great diversity of rod-shaped bacteria (short, middle and long).
After		5 mm	no	99.9%	Biofilm amount decreased ($\sim 1 \times 10^4$ bacteria), while the same morphotypes were observed.
Before	21 ml	7 mm	yes		Densely composed biofilm ($\sim 1 \times 10^6$ bacteria) with all types of rod-like morphotypes.
After		3 mm	yes	100.0%	Eukaryotic cells; no evidence of bacteria.
Before	27 ml	6 mm	yes		Biofilm ($\sim 1 \times 10^6$ bacteria) embedded in its extracellular matrix.
After		5 mm	yes	99.85%	Few patches of biofilm ($\sim 5 \times 10^3$ bacteria) consisting of rod shaped bacteria with varying length.
Before	31 dl	8 mm	yes		Densely embedded biofilm ($\sim 1 \times 10^7$ bacteria) revealing large numbers of Treponema-like morphotypes.
After		3 mm	no	99.99%	Eukaryotic cells and small biofilm colonies ($\sim 5 \times 10^3$ bacteria) with rod shaped morphology.

Type I periodontal disease and was treated for 10 minutes twice daily for five weeks; pocket probing depth decreased 2–3 mm at the sites analyzed, no bleeding on probing was seen at any site, and no bacteria were recovered from three of four sites sampled

after five weeks. Patient 3 had Type IV periodontal disease on arrival at the clinic, and was treated for 15 minutes six times daily for two weeks; no bleeding on probing was seen, and pocket probing depth decreased 1–5 mm at the sites analyzed after two

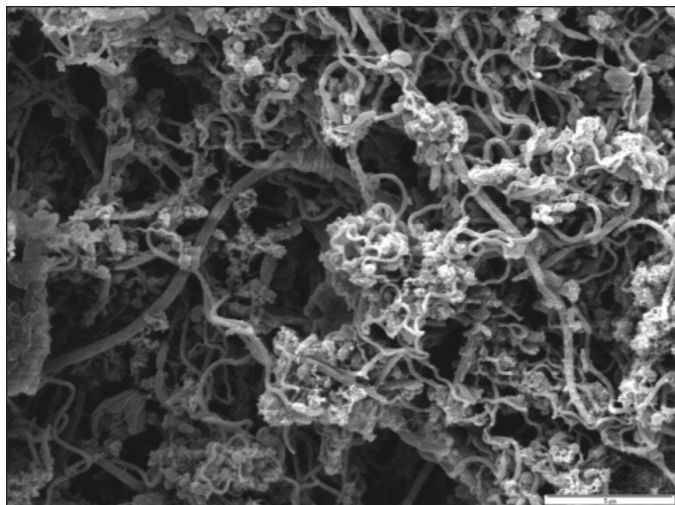


Figure 6a. Patient 1 SEM from paper point sample 24 mb before treatment indicates predominance of *Treponema*-like morphotypes.




Figure 6b. Patient 1 SEM from paper point sample 24 mb after five weeks' daily treatment shows multi-layered biofilm with short rods, long rods, and coccus-like morphotypes.

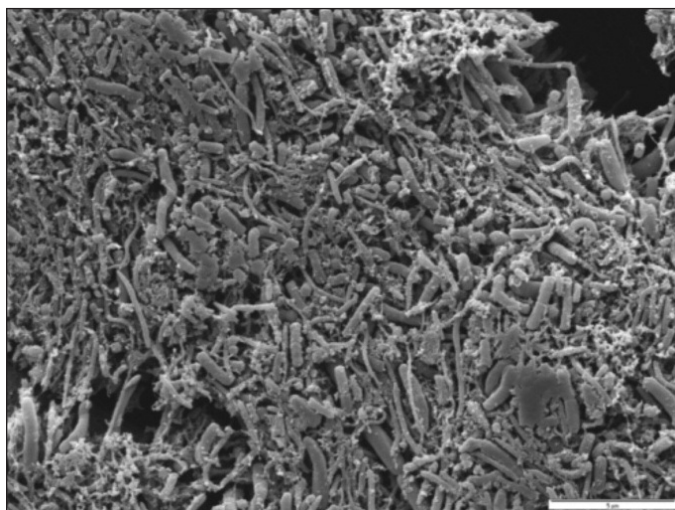


Figure 7a. Patient 2 SEM from paper point sample 14 mb before treatment indicates dense multi-layered biofilm with *Treponema*-like bacteria and rods of different lengths.




Figure 7b. Patient 2 SEM from paper point sample 14 mb after five weeks' daily treatment. No bacteria were found.

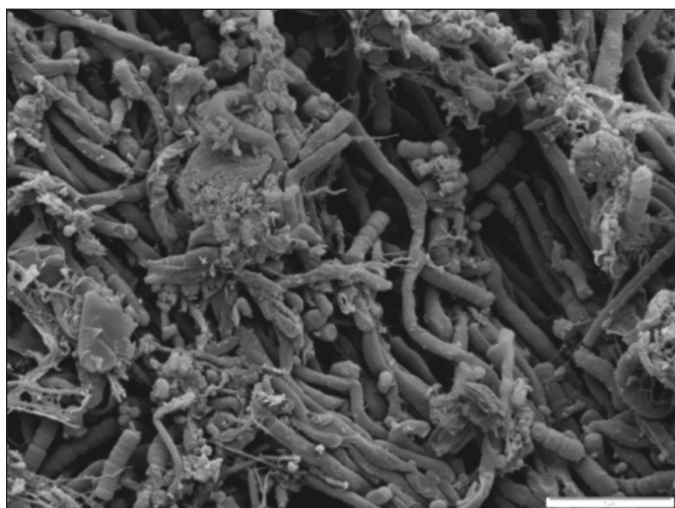


Figure 8a. Patient 3 SEM from paper point sample 31 mb before treatment indicates multi-layered biofilm with high number of *Treponema*-like morphotypes.

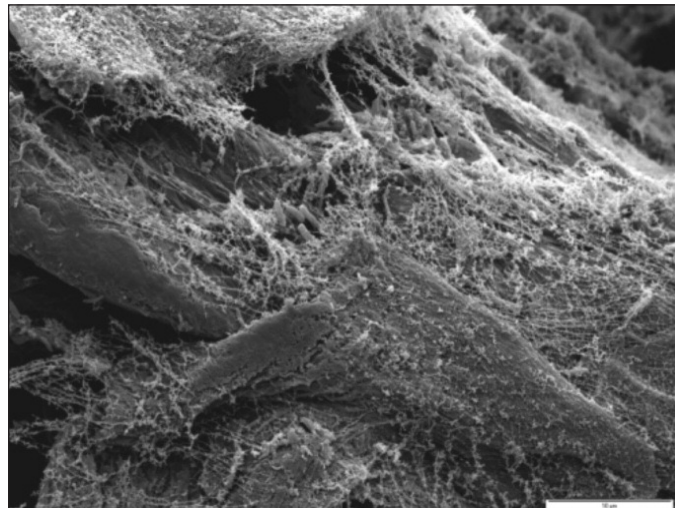


Figure 8b. Patient 3 SEM from paper point sample 31 mb after two weeks' daily treatment indicates sparse biofilm and eukaryotic cells.

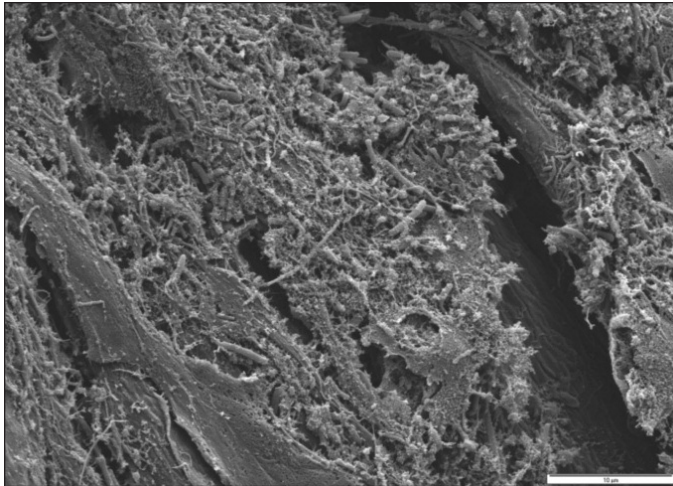


Figure 9a. Patient 4 SEM from paper point sample 21 ml before treatment indicates biofilm composed of rod-like morphotypes.




Figure 9b. Patient 4 SEM from paper point sample 21 ml after two weeks' daily treatment indicates presence of eukaryotic cells and no bacteria.

weeks of Perio Tray delivery of medication. Additionally, no bacteria were recovered from paper points at three of five sites after two weeks of treatment. Patient 4 had Type IV periodontal disease at the time of treatment, and no bleeding on probing at three of six sites was seen after two weeks of six times daily use of medication in the Perio Tray for 15 minutes. Pocket probing depth decreased 0–5 mm during this time; two treated sites had no bacteria present after treatment. In all cases after treatment when bacteria were observed on paper points, the recovery was reduced compared to the initial sampling.

Discussion

The mathematical diffusion modeling indicates hydrogen peroxide can effectively be placed into deep periodontal pockets (> 6 mm) with Perio Trays, and that concentration of hydrogen peroxide increases over time in the absence of degrading enzymes like catalase or peroxidase. Even with a relatively large GCF flow, the medication theoretically diffuses into 9 mm deep pockets within the 15-minute time period evaluated.

Hydrogen peroxide (1.7%) was chosen as the treatment agent for this diffusion modeling exercise because in prior studies, aqueous solutions of hydrogen peroxide (> 1%) have been shown to decrease plaque and gingivitis indices,^{47,48} to have antimicrobial effects on bacteria associated with periodontal disease,^{49,50} and to enhance wound healing after gingival surgery.³⁷ In addition, the biofilm potential technique^{1,51} provides case study evidence of subgingival biofilm suppression in 6 mm pockets after Perio Tray delivery (20 minutes, four times a day for five days) of 1.5% hydrogen peroxide (Peroxyl®, Colgate-Palmolive Company, New York, NY, USA) alone, and then in combination with three drops of Sumycin® Syrup (125 mg/5ml, Par Pharmaceuticals, Woodcliff Lake, NJ, USA) for two five-day periods.^{34,52}

While the debriding effects of hydrogen peroxide on oral biofilm were confirmed with the *in vitro* study presented here and the previously published case study, the strictly controlled clinical environment of the previously published case study does not take into consideration patient compliance with a patient tray delivery system. Real-world patients often do not adhere to prescribed treatment regimens,^{53,54} and the patients whose pathology

reports were reviewed here self-reportedly did not strictly comply with treatment protocols; they missed one or more of the daily recommended treatments, or did not sustain treatment for the recommended 10 or 15 minutes. Nevertheless, the pathology reports establish *in vivo* evidence of subgingival biofilm debridement after Perio Tray placement of medication, even without strictly controlled conditions.

Direct visualization with SEM in these pathology reports differs from DNA analysis primarily in that standard DNA-Polymerase Chain Reaction tests (commercially available with OralDNA® Labs, Brentwood, TN, USA and Hain Diagnostics, LLC, Midland, TX, USA) evaluate a relatively small number of selected bacterial species, whereas SEM offers an indiscriminate view of the entire biofilm. Neither procedure can discriminate between living and dead bacteria.

In addition to the evidence of biofilm suppression, an overview of the pathology reports indicates that the prescription tray delivery of 1.7% hydrogen peroxide and three drops of Vibramycin helped reduce pocket depths and bleeding on probing, a confirmation that the prescribed solutions were held in place long enough for the medication to have a therapeutic effect. Yet because the reductions were not uniform, the tray delivery of prescribed solutions may only be suggested as an adjunct to a comprehensive treatment plan implemented under the supervision of a dentist. In clinical practice, use of the prescription tray delivery of medication is often followed by full mouth debridement, site-specific scaling as needed, site-specific surgery when needed, and prophylaxis.

While the *in vitro* results indicate that hydrogen peroxide is effective on oral biofilms, their debriding action on *in vivo* subgingival biofilms cannot be confirmed with the pathology reports because hydrogen peroxide and Vibramycin were both used. Tetracyclines are commonly prescribed in the course of treatment for periodontal disease.⁵⁵⁻⁵⁹ For these patients, the sorbitol-based Vibramycin was prescribed for topical delivery for its anti-inflammatory properties. Further testing needs to be completed to confirm the specific therapeutic effects of individual solutions used with the prescription tray system.

Additional testing is also needed to confirm the most appropriate course of treatment with individual medications. If medication

delivered subgingivally with the Perio Tray can decrease biofilm populations, reduce pocket depths, and eliminate bleeding before mechanical debridement, then the risks of bacteremia with mechanical debridement may also be reduced, as may the extent and scope of necessary mechanical debriding procedures.

Conclusions

Theoretical *in vitro* and *in vivo* evidence presented here indicate that the custom-formed prescription Perio Tray can place and maintain medications in periodontal pockets at a sufficient concentration for the medication to have a significant therapeutic effect. *In vitro* studies established the ability of 1.7% hydrogen peroxide to debride the *S. mutans* biofilms on glass carriers. This is consistent with the action of hydrogen peroxide as an oral debriding agent. Theoretical calculations indicate hydrogen peroxide is capable of reaching deep periodontal pockets, even against gingival crevicular fluid pressure. These theoretical calculations were confirmed with the analysis of paper points placed in periodontal pockets before and after 1.7% hydrogen peroxide and a subclinical dose of Vibramycin were delivered subgingivally with the Perio Tray.

Acknowledgment: This work was supported by Perio Protect, LLC.

For correspondence with the authors of this paper, contact Dr. Milton Marshall—Milton.Marshall@uth.tmc.edu.

References

- Schaudinn C, Gorur A, Keller D, Sedghizadeh PP, Costerton JW. Periodontitis. An archetypical biofilm disease. *J Am Dent Assoc* 2009;140:978-86.
- Socransky SS, Haffajee AD. The nature of periodontal diseases. *Ann Periodontol* 1997;2:3-10.
- Travis J, Potempa J, Maeda H. Are bacterial proteases pathogenic factors? *Trends Microbiol* 1995;3:405-7.
- Rateitschak KH, Rateitschak EM, Wolf E. *Farbatlant der Zahnmedizin 1, Parodontologie*. Thieme Verlag, 1984.
- Taubman MA, Dawai T. Involvement of T-lymphocytes in periodontal disease and in direct and indirect induction of bone resorption. *Crit Rev Oral Biol Med*. 2001;12:125-35.
- Costerton J, Keller D. Oral periopathogens and systemic effects. *Gen Dent* 2007;55:210-15.
- Williams RC, Barnett AH, Claffey N, Davis M, Gadsby R, Kellett M, Lip GY, Thackray S. The potential impact of periodontal disease on general health: A consensus view. *Curr Med Res Opin* 2008;24:1635-43.
- Socransky SS, Haffajee AD, Cugini MA, Smith C, Kent RL Jr. Microbial complexes in subgingival plaque. *J Clin Periodontol* 1998;25:134-44.
- AAP statement on the efficacy of laser in the non-surgical treatment of inflammatory periodontal disease. *J Periodontol* 2011;82:513-14.
- AAP statement on the local delivery of sustained or controlled release antimicrobials as adjunctive therapy in the treatment of periodontitis. *J Periodontol* 2006;77:1458.
- Apatzidou DA, Kinane DF. Nonsurgical mechanical treatment strategies for periodontal disease. *Dent Clin North Am* 2010;54:1-12.
- Hall-Stoodley L, Hu FZ, Gieseke A, Nistico L, Nguyen D, Hayes J, Forbes M, Greenberg DP, Dice B, Burrows A, Wackym PA, Stoodley P, Post JC, Ehrlich GD, Kerschner JE. Direct detection of bacterial biofilms on the middle-ear mucosa of children with chronic otitis media. *J Am Med Assoc* 2006;292:202-11.
- Nickel JC, Costerton JW. Bacterial localization in antibiotic-refractory chronic bacterial prostatitis. *Prostate* 1993;23:107-14.
- Adriaens PA, Adriaens LM. Effects of nonsurgical periodontal therapy on hard and soft tissues. *Periodontol* 2000 2004;36:121-45.
- Zijngel V, Meijer HF, Lie MA, Tromp JA, Degener JE, Harmsen HJ, Abbas F. The recolonization hypothesis in a full-mouth or multiple-session treatment protocol: a blinded, randomized clinical trial. *J Clin Periodontol* 2010;37:518-25.
- Resposo S, Tobler J, Alfant B, Gollwitzer J, Walker C, Shaddox L. Poster presentation: Differences between Biofilm Growth Before and After Periodontal Therapy. AADR 37th Annual Meeting. April 3, 2008. Abstract available online.
- Palmer RJ, Caldwell DE. A flowcell for the study of plaque removal and regrowth. *J Micro Methods* 1995;24:171-82.
- Darby I. Non-surgical management of periodontal disease. *Aust Dent J* 2009;54(Suppl):S86-95.
- Krayer JW, Leite RS, Kirkwood KL. Non-surgical chemotherapeutic treatment strategies for the management of periodontal diseases. *Dent Clin North Am* 2010;54:13-33.
- Tuomanen E, Cozens R, Tosch W, Zak O, Tomasz A. The rate of killing of *Escherichia coli* by beta-lactam antibiotics is strictly proportional to the rate of bacterial growth. *J Gen Microbiol* 1986;132:1297-1304.
- Stewart PS. Theoretical aspects of antibiotic diffusion into microbial biofilms. *Antimicrob Agents Chemother* 1996;40:2517-22.
- Schara R, Medvescek M, Skaleric U. Periodontal disease and diabetes metabolic control: a full-mouth disinfection approach. *J Int Acad Periodontol* 2006;8:61-6.
- Lafaurie GI, Mayorga-Fayad I, Torres MF, Castillo DM, Aya MR, Barón A, Hurtado PA. Periodontopathic microorganisms in peripheral blood after scaling and root planing. *J Clin Periodontol* 2007;34:873-9.
- Morozumi T, Kubota T, Abe D, Shimizu T, Komatsu Y, Yoshie H. Effects of irrigation with an antiseptic and oral administration of azithromycin on bacteremia caused by scaling and root planing. *J Periodontol* 2010;81:1555-63.
- Fischer MA, Borgnakke WS, Taylor GW. Periodontal disease as a risk marker in coronary heart disease and chronic kidney disease. *Curr Opin Nephrol Hypertens* 2010;19:519-26.
- Johnson JD, Chen R, Lenton PA, Zhang G, Hinrichs JE, Rudney JD. Persistence of extracrevicular bacterial reservoirs after treatment of aggressive periodontitis. *J Periodontol* 2008;79:2305-12.
- Tribble GD, Lamont RJ. Bacterial invasion of epithelial cells and spreading in periodontal tissue. *Periodontol* 2000 2010;52:68-83.
- Dorn BR, Dunn WA, Progluske-Fox A. Invasion of human coronary artery cells by periodontal pathogens. *Infect Immun* 1999;67:5792-8.
- Bermudez LE, Goodman J, Petrofsky M. Role of complement receptors in uptake of *Mycobacterium avium* by macrophages *in vivo*; evidence from studies using CD18-deficient mice. *Infect Immun* 1999;67:4912-6.
- Lamont RJ. Bacterial invasion of host cells. *Adv Molecul Cell Microbiol*. Cambridge University Press 2004.
- Keller D. How to manage oral biofilm using perio protect as a minimally invasive method for lasting oral health. *DPR* 2010;44:54-55.
- Keller D. Managing periodontal disease in a patient suffering from renal failure. *Dent Today* 2008;27:144-7.
- Keller D, Nguyen LT, Jobe LR, Sindelar BJ. Poster presentation: Preliminary data on periodontal disease treatment using topical oxidizing agents. AADR (March 3-6, 2010), Washington DC. Abstract available online: <http://iadr.confex.com/iadr/2010dc/webprogram/Paper130185.html>.
- Schaudinn C, Gorur A, Sedghizadeh P, Costerton J, Keller D. Manipulation of the microbial ecology of the periodontal pocket. *World Dent* 2010 Feb-March: 14-18.
- Lazarchik DA, Haywood VB. Use of tray-applied 10 percent carbamide peroxide gels for improving oral health in patients with special-care needs. *J Am Dent Assoc* 2010;141:639-46.
- 21 CFR Parts 201, 356, and 369. Federal Register, Vol 53. No. 17. Wednesday, January 27, 1988.
- Marshall MV, Cancro LP, Fischman SL. Hydrogen peroxide. A review of its uses in dentistry. *J Periodontol* 1995;66:786-96.
- Gerlach RW, Barker ML, Sagel PA, Ralston CS, McMillan DA. In-use peroxide kinetics of 10% hydrogen peroxide whitening strips. *J Clin Dent* 2008;19:59-63.
- Ikai H, Nakamura K, Shirato M, Kanno T, Iwasawa A, Sasaki K, Niwano Y, Kohno M. Photolysis of hydrogen peroxide, an effective disinfection system via hydroxyl radical formation. *Antimicrob Agents Chemother* 2010;54:5086-91.

40. Gusberti FA, Sampathkumar P, Siegrist BE, Lang NP. Microbiological and clinical effects of chlorhexidine digluconate and hydrogen peroxide mouthrinses on developing plaque and gingivitis. *J Clin Periodontol* 1988;15:60-7.
41. Nocker A, Mazza A, Masson L, Camper AK, Brousseau R. Selective detection of live bacteria combining propidium monoazide sample treatment with microarray technology. *J Microbiol Methods* 2009;76:253-61.
42. Koo H, Xiao J, Klein MI, Jeon JG. Exopolysaccharides produced by *Streptococcus mutans* glucosyltransferases modulate the establishment of microcolonies within multispecies biofilms. *J Bacteriol* 2010;192:3024-32.
43. Goodson JM. Gingival crevice fluid flow. *Periodontol* 2000 2003;31:43-54.
44. Wentz LE, Blake AM, Keller DC, Sindelar BJ. Initial study of the Perio Protect treatment for periodontal disease. *J Dent Res* 2006;85(Spec Iss A):1164.
45. Treybal RE. Mass-transfer operations. McGraw-Hill, New York, p. 26, 1980.
46. US Peroxide, LLC. Coefficient of diffusion. 2009. <http://www.h2o2.com/technical-library>. Accessed 10/29/2010.
47. Boyd RL. Effects on gingivitis of daily rinsing with 1.5% H₂O₂. *J Clin Periodontol* 1989;16:557-62.
48. Gomes DC, Shakun ML, Ripa LW. Effect of rinsing with 1.5% hydrogen peroxide solution (Peroxyl) on gingivitis and plaque in handicapped and non-handicapped subjects. *Clin Prev Dent* 1984;6:21-5.
49. Miyasaki KT, Genco RJ, Wilson ME. Antimicrobial properties of hydrogen peroxide and sodium bicarbonate individually and in combination against selected oral, Gram-negative, facultative bacteria. *J Dent Res* 1986;65:1142-8.
50. Fletcher RD, Brastins ED, Albers AC, Conway J. The effect of the Keyes procedure *in vitro* on microbial agents associated with periodontal disease. *Quintessence Int* 1984;3:329-34.
51. Wecke J, Dersten T, Madela K. A novel technique for monitoring the development of bacterial biofilms in human periodontal pockets. *FEMS Microbiol Lett* 2000;191:95-101.
52. http://iadr.confex.com/iadr/2007orleans/techprogram/abstract_88428.htm.
53. Eisen SA, Miller DK, Woodward RS, Spitznagel E, Przybeck TR. The effect of prescribed daily dose frequency on patient medication compliance. *Arch Intern Med*. 1990;150:1881-4.
54. Cramer JA, Lynch NO, Gaudin AF, Walker M, Cowell W. The effect of dosing frequency on compliance and persistence with bisphosphonate therapy in postmenopausal women: a comparison of studies in the United States, the United Kingdom, and France. *Clin Ther* 2006;28:1686-94.
55. Gu Y, Lee HM, Sorsa T, Simon SR, Golub LM. Doxycycline [corrected] inhibits mononuclear cell-mediated connective tissue breakdown. *FEMS Immunol Med Microbiol* 2010;58:218-25.
56. Soory M. A role for non-antimicrobial actions of tetracyclines in combating oxidative stress in periodontal and metabolic diseases: a literature review. *Open Dent J* 2008;2:5-12.
57. Payne JB, Golub LM, Stoner JA, Lee HM, Reinhardt RA, Sorsa T, Slepian MJ. The effect of subantimicrobial-dose-doxycycline periodontal therapy on serum biomarkers of systemic inflammation: A randomized, double-masked, placebo-controlled clinical trial. *J Am Dent Assoc* 2011;142:262-73.
58. Almazin SM, Dziak R, Andreana S, Ciancio SG. The effect of doxycycline hyclate, chlorhexidine gluconate, and minocycline hydrochloride on osteoblastic proliferation and differentiation *in vitro*. *J Periodontol* 2009;80:999-1005.
59. Gupta R, Pandit N, Aggarwal S, Verma A. Comparative evaluation of subgingivally delivered 10% doxycycline hyclate and xanthan-based chlorhexidine gels in the treatment of chronic periodontitis. *J Contemp Dent Pract* 2008;9:25-32.